

## Hepatozoon procyonis Richards, 1961, in a Panamanian raccoon, *Procyon cancrivorus panamensis* (Goldman)

by

Curt R. Schneider \*

(Received for publication October 17, 1966)

In June, 1965, a crab-eating raccoon, *Procyon cancrivorus panamensis* (Goldman), was purchased at Gorgas Memorial Laboratory from an itinerant vendor. The animal was an adult male, said to have been caught near the town of Pacora, east of Panama City, on the Pacific side of the Isthmus. The animal seemed to be in excellent health and no hematozoa were seen in thin blood smears taken from one ear at the time of acquisition. In line with the purpose for which it was obtained, the raccoon was employed in an experiment to test the infectivity of a strain of mouse-adapted *Besnoitia*, involving the intraperitoneal inoculation of large numbers of these organisms. After 3 months of caged isolation during which no clinical signs of disease were noted, the raccoon was killed. Thin smears of heart blood were prepared, and pieces of heart, lung, spleen and liver were fixed in Zenker's fluid and sections were cut and stained in periodic-acid-Schiff stain (PAS) and hematoxylin-eosin. No *Besnoitia* stages were found in any of the sections examined, but in some sections prepared from two different blocks of myocardium, there were seen small, thin-walled cysts eventually identified as hemogregarine schizonts. A subsequent re-examination of the blood smears taken from this animal at the time of autopsy revealed a sparse number of hemogregarines in the monocytes.

The hemogregarines of mammals have been placed by WENYON (28) in the single genus *Hepatozoon*. RICHARDS (24) described *H. procyonis* from a raccoon, *Procyon lotor*, in southwestern Georgia. The present parasite agrees closely with Richards' description and undoubtedly represents the second recorded finding of *H. procyonis*.

\* Gorgas Memorial Laboratory, Panamá, R. P. Present address: Research Division, Parke Davis & Co., 2800 Plymouth Road, Ann Arbor, Michigan 48106, U.S.A.

With regard to mammalian hemogregarines, DARLING (4) reported the presence of *Hepatozoon muris* in Norway rats from Panama City; but to my knowledge there is no previous report from Panama of a hemogregarine from the raccoon or any other carnivore. The present paper describes the parasites found in the crab-eating raccoon and supplements the original species description with some additional data and figures. The parasite is also discussed in relation to hemogregarines of mammals in general and other carnivores in particular. Data on the sporogonic cycle are not available.

## DESCRIPTION OF THE PARASITE

**THE SCHIZONT.** Schizonts were found only in myocardium. None was seen in liver, lung, or spleen, and bone marrow was not examined. In myocardium the parasites were sparse; however, a number of different developmental stages was found, ranging from what is apparently a very young schizont (Fig. 1) to mature schizocysts from which merozoites appear to have escaped (Figs. 6-7). The cystic nature of these schizonts was indicated by the thin, limiting membrane (Figs. 2, 4, 6), which was never thicker than 1.5 microns and generally thinner. A distinction between large schizonts with small merozoites and small schizonts with large merozoites, such as reported by WENYON (27) for *H. canis*, was not noted in the present material. Schizonts appeared oval or circular in section, depending on the plane of the cut. Measurements may be summarized as follows: Length of schizonts (7 measured): 40.3 microns (range: 24.9 - 52.0). Width of schizonts (15 measured, including 8 seen in cross section only): 27.1 microns (range: 18.0 - 38.8).

The mature schizont, or schizocyst, was characterized by the presence of a large central body surrounded by individual merozoites (Fig. 5). The central, or residual, body was composed of discrete granules, about 1.5 microns in diameter, which took an intense magenta color with PAS stain and appeared to be composed of glycogen. In the structures thought to represent earlier schizonts the glycogen granules were generally interspersed with the developing merozoites; these stages were molar in appearance and details could not be made out because of the uniformly dark color. On occasion, however, the contents were scattered by the knife, and individual elements could be seen (Fig. 3).

Mature merozoites contained compact nuclei as well as discrete granules of chromatin scattered through the cytoplasm (Fig. 5). In three instances, the entire merozoite was found lying in the same focal plane; it was then seen to possess a filiform extension of one end (Fig. 7, 8a, 8b). The lengths of the three merozoites were 7.7, 8.4, and 10.0 microns.

The number of merozoites in a mature schizont could not easily be determined from the sections, but it was estimated that the number was greater than 100.

**PATHOLOGY.** Sections of 5 different blocks of tissues cut from different sites on the heart were examined. All sections revealed an active myocarditis of the focal type. Although the lesions were seen in all sections, cysts of *Hepatozoon* were found in only 2 of the blocks, often in close association with pockets of infiltrating leucocytes containing gametocytes (Fig. 9).

**THE GAMETOCYTE.** The search for these stages was pressed after the nature of the tissue schizonts was recognized. The gametocytes were sparse, only 20 being found after considerable search of several thin smears. Gametocytes were found only in the monocytes; none was seen in neutrophils, eosinophils or lymphocytes. Infected monocytes were found only in the leading edge of the smear, where heavier formed elements in the blood tend to collect.

The gametocyte was usually in contact with the host cell nucleus (Figs. 10, 17, 20) or rather deeply embedded in it (Figs. 13, 15, 16, 21) but an occasional example did not show this (Fig. 19). The parasite did not appear to be karyolytic and host cell nuclei seemed undamaged. Parasitized monocytes seemed to be no larger than uninfected ones.



The gametocytes possessed a distinct capsule, somewhat longer than the vermicle inside and with the free, or unoccupied, portion turned over on itself or twisted to form a terminal flap. RICHARDS (24) called it a recurved "tail". In many cases, this flap contained 3 to 8 highly refractile granules which, with Giemsa, stained a dark magenta color, similar to that of the host cell nucleus. This "flap" is seen in Figures 10-16, 18, 19, 21, but is best shown in Figure 18. RICHARDS (24) pictured only a single granule in the free flap of each of his two figures of gametocytes. If more material eventually becomes available, this feature may prove to be somewhat variable; granules were not always visible in the present slides. (Fig. 14). But, when present, such granules give a very distinctive appearance to the parasite.

Gametocytes were not "tailed" or doubled upon themselves to form a "U" inside the capsule, but lay in it in the form of a cylindrical or ovate body which did not completely fill it. One end of the gametocytes was often occupied by a clear space or vacuole, which gave a truncated appearance to the gametocyte (Figs. 11, 12, 14, 19). The measurements of 20 gametocytes, given in microns, were as follows: Length of capsule, not including free flap: 8.2 (range: 7.5 - 8.7). Length of capsule plus flap (9 measured): 11.7 (range: 10.0 - 12.5). Width of capsule: 3.7 (range: 2.9 - 4.2). Length of vermicle: 5.5 (range: 4.6 - 6.6). Width of vermicle: 2.5 (range: 2.1 - 2.9). Length of nucleus (14 measured): 3.5 (range: 2.9 - 4.6). Width of nucleus (14 measured): 2.3 (range: 1.7 - 2.9).

The cytoplasm of the gametocyte was colored a faint sky-blue with Giemsa and the nucleus, when seen, was magenta. In some, the nucleus did not stain, although the cytoplasm could be distinguished (Figs. 13, 15-17), suggesting that the capsule was not impermeable but that the nucleus in these cases was either absent or possessed different staining characteristics from those of gametocytes in which it was clearly seen. It is possible that this difference indicates a sexual dimorphism; however, other investigators have reported that sexual differences in leucocyte-inhabiting hemogregarines are not seen (10, 12, 16). The well-stained nucleus appeared to be compact (Fig. 12), or granular (Fig. 11) or both (Figs. 18, 19, 21). Dispersed granules of chromatin were not seen in the cytoplasm of the gametocytes.

The nucleus was judged to be in a terminal position in 5 examples, subterminal in 3 and central in 6. No nucleus could be seen in 6 of the gametocytes.

## DISCUSSION

The known mammalian hemogregarines do not form a large group. They have been reported from marsupials, rodents, and carnivores. MACKERRAS (14) states that they further fall into two groups, (i) those which are found in circulating leucocytes, and (ii) those found in erythrocytes. The present parasite, like those previously described from carnivores, falls in the first group.

Hemogregarines have been described from the following carnivores, representing the families Canidae, Felidae, Hyacnidae, Viverridae, and Procyonidae: domestic dog (2, 7, 11, 15, 27), jackal (17, 19), fox (23), hyena (12), domestic cat (18), lion (1), leopard, genet cat (1, 8), palm civet (11), and raccoon (24).

The carnivore hemogregarines fall readily into two geographic groups. i) Those reported from Asia, Africa, and southern Europe can all be referred to *H. canis* on the basis of morphology and life cycle, where known (13). According to KRAMPITZ (9), *H. canis* has never been reported from the Western Hemisphere. ii) The only carnivore hemogregarine thus far known from the Americas (southwestern Georgia and Panama) is *H. procyonis*. It differs in certain

notable respects from *H. canis* and is not likely to be synonymized with it. The differences are as follows:

1) The free "flap" of the gametocyte capsule, with its beaded appearance, is an unusual feature which has not been described from any other species of *Hepatozoon*. (Parenthetically, it may be pointed out that RICHARDS (24) found 2 of 6 fox squirrels (*Sciurus niger*) to be infected with *Hepatozoon*. This parasite was not identified specifically but was stated to be morphologically different from *Hepatozoon griseisciuri* Clark, 1958. In one of Richards' figures, the gametocyte is shown with a recurved end, although this feature was stated to be rare in his material. The squirrels and raccoons included in Richards' collection all came from the same locality and it is not impossible that the same parasite was represented in both hosts. On the other hand, his squirrel gametocytes were noticeably larger than the equivalent raccoon stages. In addition, the magenta-staining granules lining the flap of the capsule were not reported or figured for the squirrel gametocytes).

2) Circulating hemogregarines of a given species show a partiality for certain host cell types and are rarely found parasitizing any but these types. Thus, *H. canis* is seen in neutrophils (2, 27), whereas the rodent-parasitizing forms which utilize leucocytes are almost invariably found in monocytes (3, 16, 20). The equivalent stages in marsupial hosts seem to be limited to erythrocytes (14, 26). In this regard, *H. procyonis*, which is found in monocytes, bears a closer resemblance to the cosmopolitan rodent forms than to *H. canis*.

3) Heart muscle has been reported as a site for schizogony only in the case of *H. procyonis* (24, and the present paper). In *H. canis* the developmental stages of the asexual cycle occur in spleen and bone marrow (2, 27) or liver (22). The rodent schizonts have been found in bone marrow (20) and spleen (3, 25). In marsupials, schizonts were found in pancreas<sup>1</sup> (26).

In addition to these characteristics of *H. procyonis*, some attention should be given to the "vermicular" merozoites which are pictured in Figures 7, 8a and 8b. Merozoites of this shape have not previously been reported for hemogregarines, although some species are known to adopt a vermicular appearance as gametocytes. It is entirely possible that the merozoites of many hemogregarines adopt such a shape just before leaving the schizocyst and entering blood cells. If this is true, the "tailed" merozoites seen in *H. procyonis* may prove to be characteristic of the whole group. Until this is demonstrated, however, the presence of "tailed" or vermicular merozoites in mature schizonts may be added to the distinguishing characteristics of *H. procyonis*.

The hemogregarines of rodents and marsupials are not known to cause disease, but a febrile condition of Old World dogs, associated with *H. canis* infection and characterized by progressive emaciation, anemia and other signs, has been reported by RAO (22), RAHIMUDDIN (21), and EL HINDAWY (5).

1. Preliminary reports of the discovery of *Hepatozoon* gametocytes in circulating lymphoid cells and schizonts in cardiac muscle of leopards and genet cats in Kenya and Zambia (1, 8) still await confirmation.



With regard to infection with *H. procyonis*, clinical disease has not been reported. RICHARDS (24) found no evidence that the host was harmed at all by this hemogregarine. But in the present material, definite microscopic pathology was noted. The inflammation, focal in nature, was probably associated with the presence of schizonts. The lesions included pockets of infiltrating white cells which showed many cells containing hemogregarines. A similar lesion was pictured by RICHARDS (24). It is interesting to speculate, from this, that the infection of monocytes may be an entirely passive process on the part of the parasite: thus, merozoites, upon leaving the mature schizonts, may attract monocytes, be ingested by them and so eventually, get into the circulation.

There is a disparity between the measurements of stages of *H. procyonis* recorded by RICHARDS (24) from *Procyon lotor* and those presented here from *P. cancrivorus*. The gametocytes in Richards' material are only slightly larger; the capsules (without "tail") from *P. lotor* measured  $10.9 \times 5.4$  microns, while those from *cancrivorus* were  $8.2 \times 3.7$  microns. But the schizonts in *lotor* were almost twice the size of those in *cancrivorus*;  $50 \times 80$  microns as opposed to  $27 \times 40$  microns. The reason for this is not apparent. The difference may be due to the fact that two species of host are involved and may react somewhat differently to the parasite. Or the difference may be individual. More material would be needed to clarify this point.

Raccoons are widely distributed in the Americas and the ranges of the two known species overlap in Panama. Thus, *Procyon lotor* occurs from southern Canada to Panamá while *P. cancrivorus* is found from Costa Rica and Panama as far as southern Brazil (6). Considering this range and overlap, it is thought that the distribution of the raccoon hemogregarine may prove to be continuous, limited only by the availability of its unknown vector. Thus, a careful search may eventually reveal the parasite in raccoons from other localities in Central America, Mexico, and southern United States.

### ACKNOWLEDGMENTS

My thanks are due to Mr. Tomás Engler for his fine technical assistance, and to Lt. Col. Bryce C. Walton, who first drew my attention to the presence of the vermicular merozoites.

### SUMMARY

*Hepatozoon procyonis* Richards, 1961, (Coccidia, Adeleina) has been found in a Panamanian crab-eating raccoon, *Procyon cancrivorus panamensis* (Goldman), a new host species record and the first report of a hemogregarine from a Panamanian carnivore. The schizonts, in myocardium, and the gametocytes, in monocytes, are described.

The following points were not included in Richards' original description: (1) The elongated, free "flap" of the gametocyte capsule contained 3 to 8 refractile granules which stained magenta with Giemsa. (2) The schizonts were associated with an active, focal myocarditis. (3) The merozoites within mature schizonts were "tailed".

## RESUMEN

*Hepatozoon procyonis* Richards, 1961, (Coccidia, Adeleina) se encontró por primera vez en un gato manglatero panameño, *Procyon cancrivorus panamensis* (Goldman), constituyendo así la primera vez que se describe una hemogregarina en un mamífero carnívoro en Panamá. Se pudo observar los esquizontes en el miocardio y los gametocitos en monocitos del huésped.

A continuación se hace referencia a unos puntos que Richards no incluyó en su descripción original: (1) La parte libre elongada de la cápsula del gametocito contiene de 3 a 8 gránulos refráctiles, que se tiñen de color púrpura rojizo con Giemsa. (2) Los esquizontes fueron vistos asociados con una miocarditis focal activa. (3) Los merozoitos dentro de los esquizontes adultos se notan con prolongaciones terminales que dan la apariencia de un rabo.

## REFERENCES

1. BROCKLESBY, D. W., & B. O. VIDLER  
1963. Some new host records for *Hepatozoon* species in Kenya. (Letter to editor) *Vet. Rec.*, 75: 1265.
2. CHRISTOPHERS, S. R.  
1906. *Leucocytozoon canis*. *Sci. Mem. Off. Med. San. Dept. Govt. India*, n. s. (26), 16 pp.
3. CLARK, G. M.  
1958. *Hepatozoon griseisciuri* n. sp.; a new species of *Hepatozoon* from the grey squirrel (*Sciurus carolinensis* Gmelin, 1788), with studies on the life cycle. *J. Parasitol.*, 44: 52-63.
4. DARLING, S. T.  
1912. Some blood parasites (*Haemoproteus* and *Haemogregarina*). *Bull. Soc. Pathol. Exot.*, 5(2): 71-73.
5. EL HINDAWY, M. R.  
1951. Studies on the blood of dogs. VI Haematological findings in some diseases caused by specific blood parasites: (a) *Babesia canis*; (b) *Hepatozoon canis*. *Brit. Vet. J.*, 107: 303-309.
6. GOLDMAN, E. A.  
1950. *Raccoons of North and Middle America*. 153 pp. North American Fauna 60. U.S. Government Printing Office, Washington, D.C.
7. JAMES, S. P.  
1905. On a parasite found in the white corpuscles of the blood of dogs. *Sci. Mem. Off. Med. San. Dept. Govt. India*, n. s. (14), 12 pp.
8. KEYMER, I. F.  
1964. *Hepatozoon* species in wild African mammals. (Letter to editor) *Vet. Rec.*, 76: 641.
9. KRAMPITZ, H. E.  
1964. Ueber das Vorkommen und Verhalten von Hemococcidien der Gattung

- Hepatozoon* Miller 1908 (Protozoa, Adeleidea) in mittel- und südeuropäischen Säugern. *Acta Trop.*, 21: 114-154.
10. KUSAMA, S., K. KASAI, & R. KOBAYASHI  
1919. The leucocytozoozoon of the wild rat, with special reference to its life-history. *Kitasato Arch. Exper. Med.*, 3: 103-122.
  11. LAIRD, M.  
1959. Malayan Protozoa 2. *Hepatozoon* Miller (Sporozoa: Coccidia), with an unusual host record for *H. canis* (James). *J. Protozool.*, 6: 316-319.
  12. LÉGER, A.  
1912. Leucocytozoaire de l'hyène tachetée du Haut-Sénégal et Niger. *Compt. Rend. Soc. Biol.*, Paris, 72: 1060-1062.
  13. LEVINE, N. D.  
1961. *Protozoan Parasites of Domestic Animals and of Man*. 412 pp. Burgess Publishing Company, Minneapolis, Minn.
  14. MACKERRAS, M. J.  
1959. The haematozoa of Australian mammals. *Austral. J. Zool.*, 7: 105-135.
  15. MARTOGGIO, F.  
1913. Contributo alla conoscenza delle leucocitogregarine. *Ann. Ig. Sper.*, n.s., 23: 161-170.
  16. MILLER, W. W.  
1908. *Hepatozoon perniciosum* (n. g., n. sp.); a haemogregarine pathogenic for white rats; with a description of the sexual cycle in the intermediate host, a mite (*Lelaps echidninus*). 51 pp. Bull. 46 Hyg. Lab., U.S. Public Health and Mar.-Hosp. Serv.
  17. NUTTALL, G. H. F.  
1910. On haematozoa occurring in wild animals in Africa. 1. *Piroplasma rossi* n. sp. and *Haemogregarina canis-adusti* n. sp. found in the jackal. 2. *Spirochaeta bovis-caffris* n. sp. found in the buffalo. *Parasitology*, 3: 108-116.
  18. PATTON, W. S.  
1908. Mammalian leucocytozoa. *Ann. Rep. Bacteriol. Sect. King Inst. Prevent. Med.*, Guindy, Madras, (1907): 3-8.
  19. PATTON, W. S.  
1910. Preliminary report on a new piroplasm (*Piroplasma gibsoni* sp. nov.) found in the blood of the hounds of the Madras hunt and subsequently discovered in the blood of the jackal *Canis aureus*. *Bull. Soc. Pathol. Exot.*, 3: 274-281.
  20. PORTER, A.  
1908. *Leucocytozoon musculi*, sp. n., a parasitic protozoön from the blood of white mice. *Proc. Zool. Soc. London*, 3: 703-716.
  21. RAHIMUDDIN, M.  
1942. *Hepatozoon canis* and its treatment. *Indian Vet. J.*, 19: 153-154.
  22. RAO, M. A. N.  
1925. *Haemogregarina canis*. *Vet. J.* (600), 81: 293-307.



23. RAO, M. A. N.  
1926. Experimental infection of the jackal (*Canis aureus*) with *Piroplasma canis*, Prana & Galli-Galerio, 1895. A preliminary note. *Indian J. Med. Res.*, 14: 243-244.
24. RICHARDS, C. S.  
1961. *Hepatozoon procyonis*, n. sp., from the raccoon. *J. Protozool.*, 8: 360-362.
25. SANGIORGI, G.  
1941. *Leucocytozoozoon cuniculi*, n. sp. *Pathologica* (125), 6: 49-50.
26. D'UTRA E SILVA, O., & J. B. ARANTES  
1917. Sobre uma hemogregarina da gambá, *Haemogregarina didelphidis* n. sp., *Mem. Inst. Oswaldo Cruz*, 8: 61-63.
27. WENYON, C. M.  
1911. Oriental sore in Bagdad, together with observations on a gregarine in *Stegomyia fasciata*, the haemogregarine of dogs and the flagellates of house flies. *Parasitology*, 4: 273-344.
28. WENYON, C. M.  
1926. *Protozoology*. 2 vols., 1573 pp. William Wood and Company, New York.
- 

Figures 1-6. Stages in the schizogony of *Hepatozoon* from myocardium of *Procyon cancrivorus*. Periodic-acid-Schiff.  $\times 1300$ .

Figure 1. Very young schizont.

Figure 2. Young schizont. Note limiting membrane.

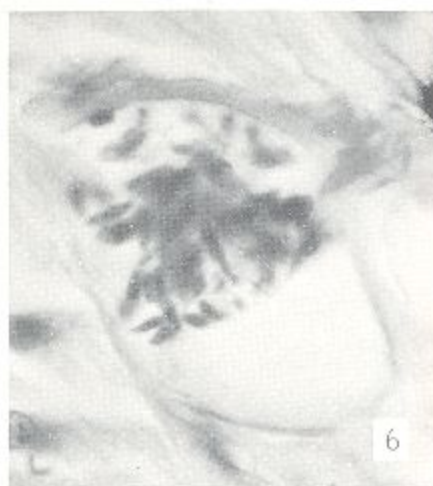
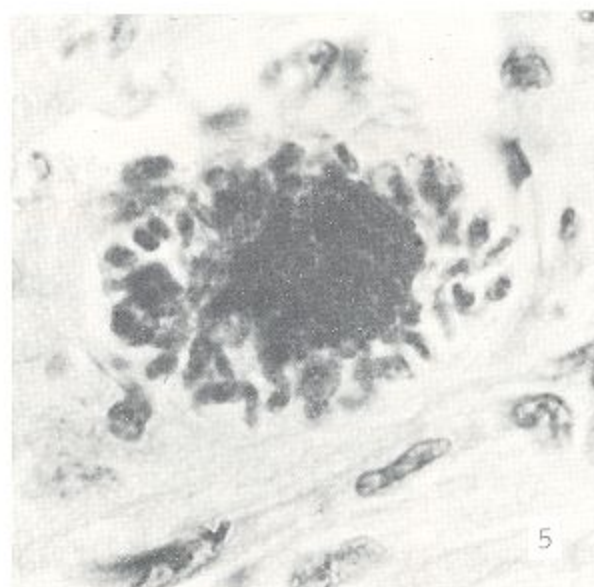
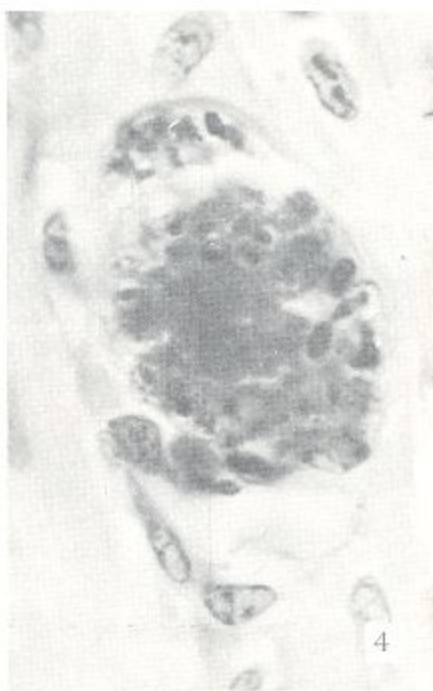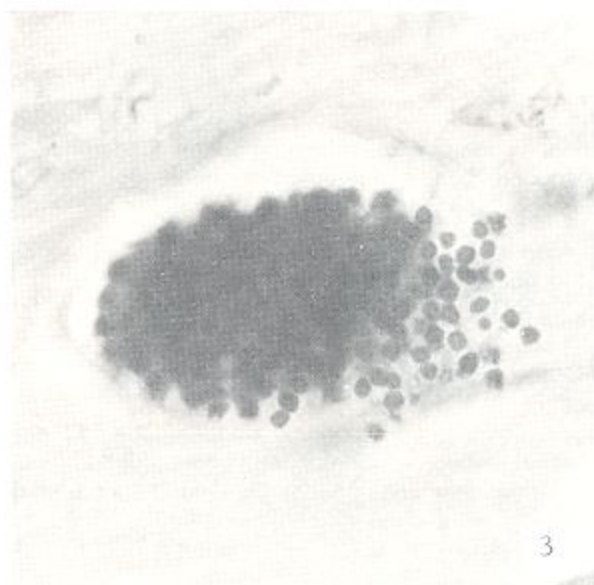
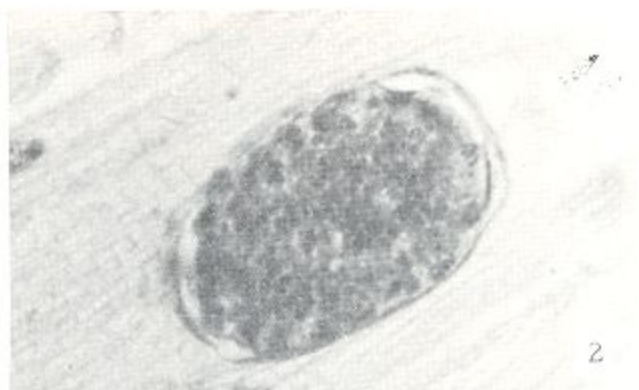
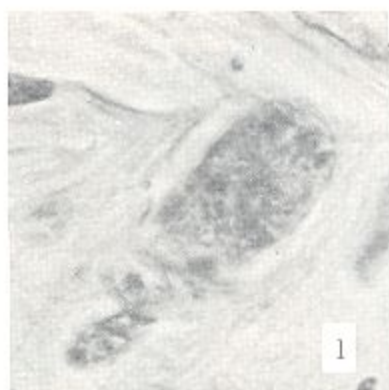
Figure 3. Typical schizont, showing discrete developing merozoites mixed with and almost indistinguishable from glycogen granules.

Figure 4. Maturing schizont, showing residual mass in center and peripheral developing merozoites.

Figure 5. Mature schizont. PAS-positive granules can be seen in individual merozoites.

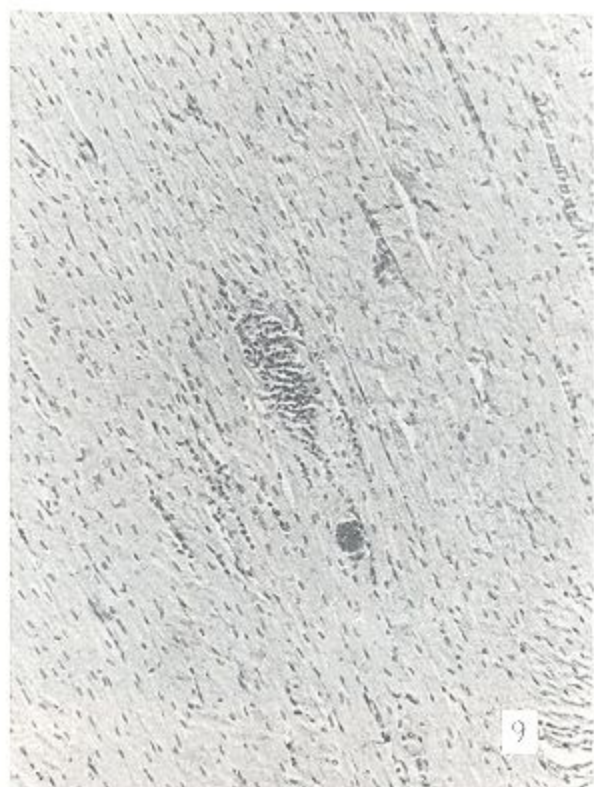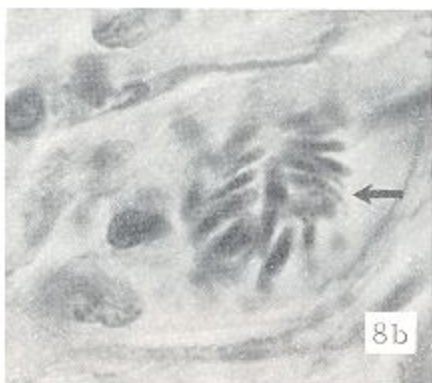
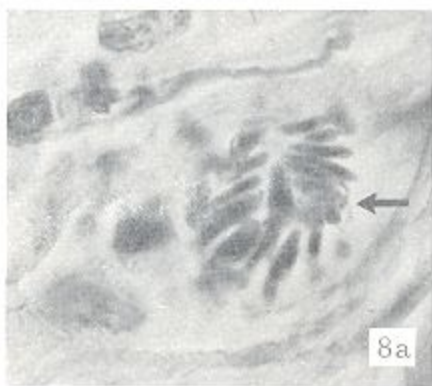
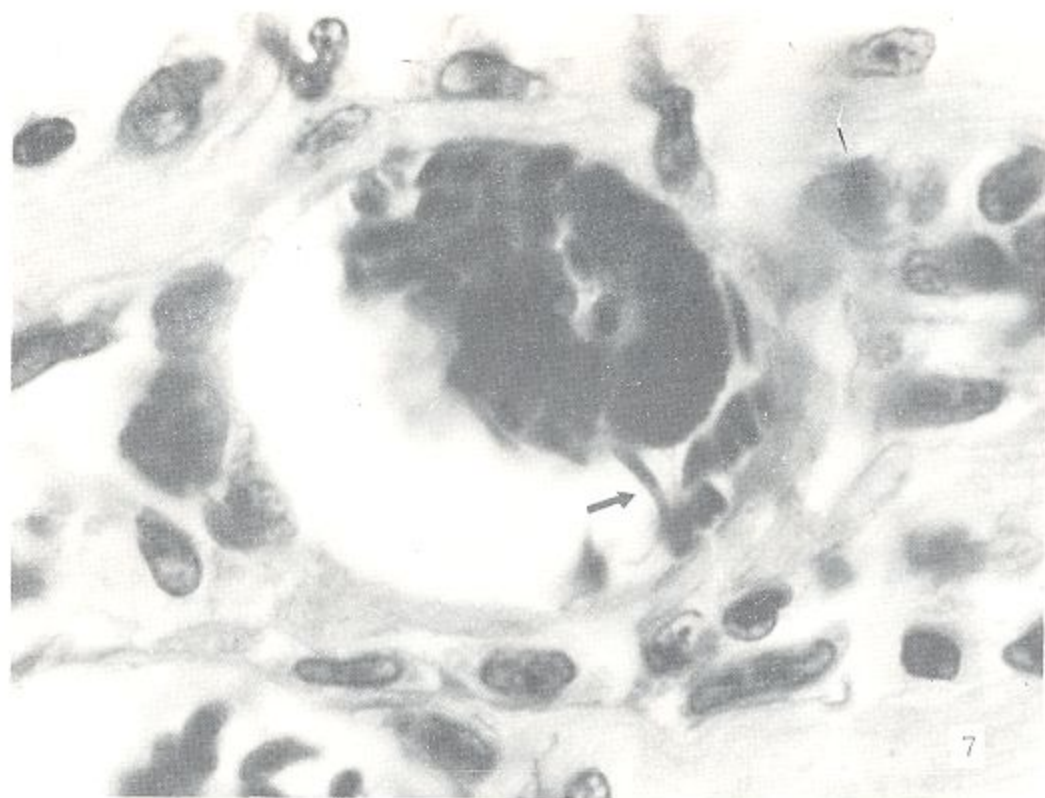
Figure 6. Mature schizont from which some merozoites have escaped.





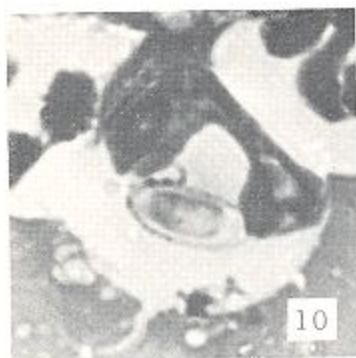
- Figure 7. Mature schizont in myocardium of *Procyon cancrivorus*. Arrow points to a mature merozoite lying entirely in one focal plane. Periodic-acid-Schiff.  $\times$  1700.
- Figures 8a, 8b. Two different focal planes of the same cyst in myocardium of *P. cancrivorus*. Arrows point to two merozoites with body and tail almost lying in the same focal plane. Periodic-acid-Schiff.  $\times$  1300.
- Figure 9. Myocardium of *P. cancrivorus* showing focal myocarditis. Note *Hepatozoon* cyst close to the large pocket of leucocytes, many of which contain gametocytes. Periodic-acid-Schiff.  $\times$  132.



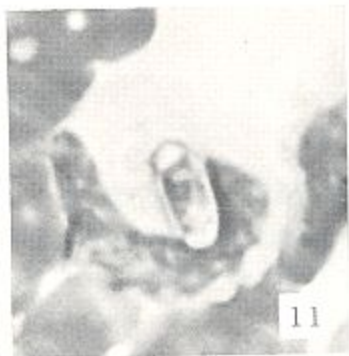


Figures 10-21. Various views of *Hepatozoon* gametocytes in thin heart-blood smears from *P. cancrivorus*. Giemsa.  $\times 1700$ .

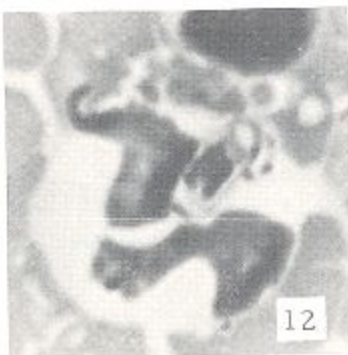




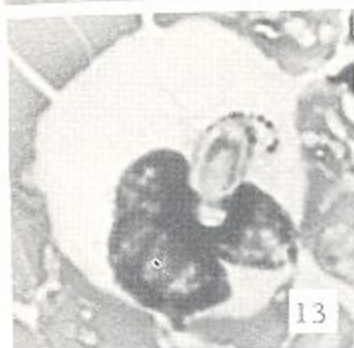10



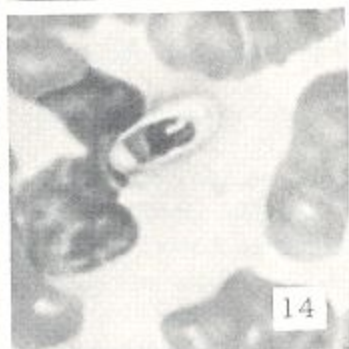
11



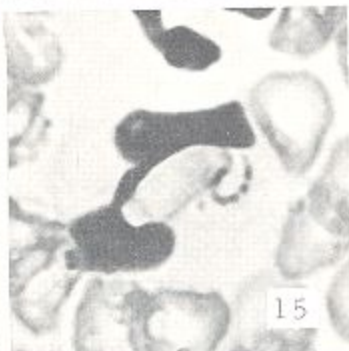
12



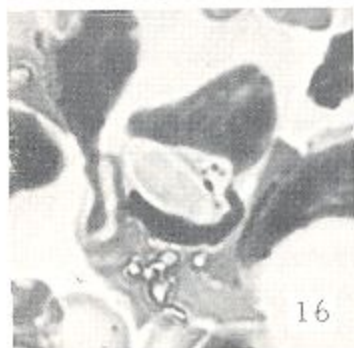
13



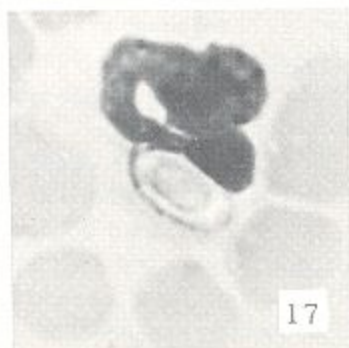
14



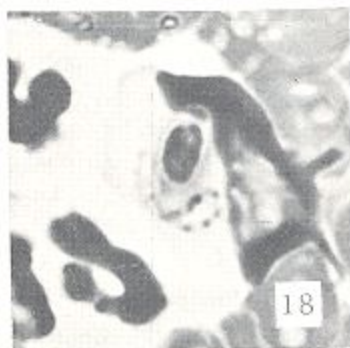
15



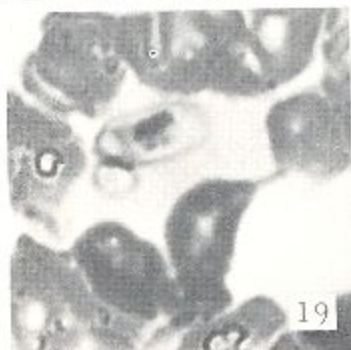
16



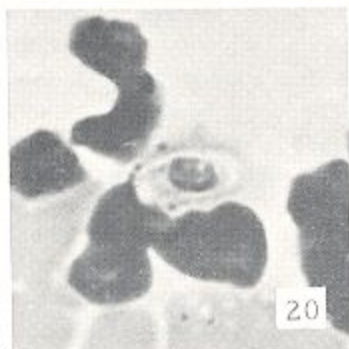
17



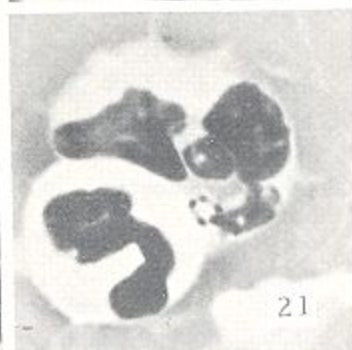
18



19



20



21